The Invisible Class IV Restoration

*Newton Fahl Jr., D.D.S., M.S.**

Edward J. Swift Jr., D.M.D., M.S.†

Advances in bonding technology have allowed the dentist to create truly esthetic restorations. However, some clinical situations still present difficult esthetic challenges. A common area of difficulty is the maxillary Class IV, where the interface between restorative material and tooth structure is frequently visible. Using a combination of composite resins, the authors present a technique for solving this problem to create esthetic, natural-looking Class IV restorations.

Using composite resin[1] with the acid-etch technique[2] and visible light–activated polymerization,[3,4] dentists can place esthetic restorations which are often indistinguishable from natural tooth structure. However, despite the available technology, achieving a good esthetic result can be very difficult in some clinical situations. A particularly challenging problem is replacement of an incisal angle lost from a maxillary incisor due to caries or traumatic fracture. Even with proper selection of materials and meticulous attention to detail, a demarcation line between tooth and restorative material is frequently observed (Fig. 1). This paper presents a simple technique for eliminating this problem in Class IV restorations.

TYPES OF COMPOSITE RESINS

A common method of classification of composite resins is based on filler particle size.[5–7] Currently-available composites are classified as small-particle, microfill, or hybrid materials. Small particle composite resins contain glass filler particles ranging in size from 1 to 8 μm. These materials have good mechanical properties, but are relatively unpolishable.

Microfilled composite resins have an average particle size of 0.04 μm. These materials can be polished smooth and to a high gloss. However, their mechanical properties, e.g., water sorption and coefficient of thermal expansion, are inferior to those of the small-particle composites.

The hybrid composites are a blend of the microfill and small-particle composites, with particle sizes generally ranging from 0.04 to about 5 μm. These composites are more polishable than the small-particle materials and have better mechanical properties (e.g., fracture strength) than the microfills.

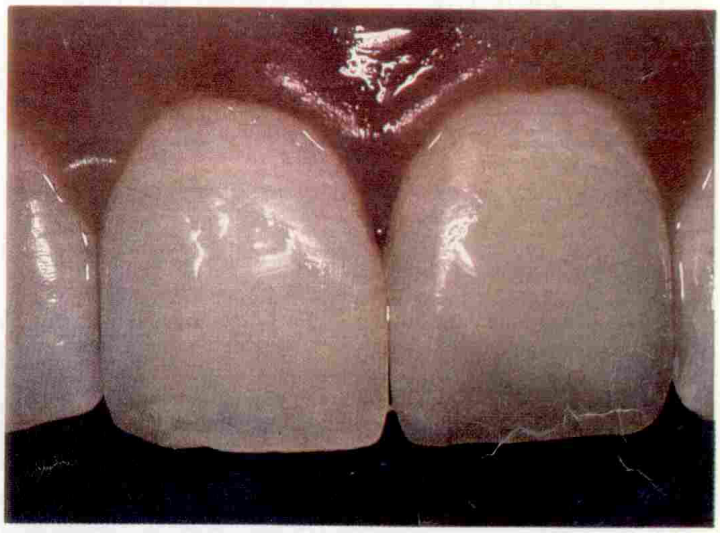

Figure 1. Typical Class IV restoration. The junction of the composite resin and tooth structure within the restoration is clearly visible.

In restoring a Class IV cavity or fracture, the dentist may select a single type or some combination of composite resins. For maximum esthetics, a microfilled resin might be selected. However, microfills are relatively weak and may not withstand the rigors of incisal function. In addition, most microfills are translucent, so light is transmitted through the material rather than reflected from it, thus lowering its value (i.e., making it appear more gray).

Therefore, a small particle or hybrid composite is preferred for adequate strength and opacity. Some operators cover the labial surface of these restorations with a microfilled resin for better esthetics.[6]

CLINICAL CASE

The patient, a 22-year-old female, reported with a

*Former Graduate Student, Department of Operative Dentistry, The University of Iowa, Iowa City, Iowa; Private Practitioner, Londrina, Brazil..

†Assistant Professor, Department of Operative Dentistry, The University of Iowa, Iowa City, Iowa.

Address reprint requests to Edward J. Swift Jr., D.M.D., M.S., Department of Operative Dentistry, The University of Iowa, Iowa City, IA 52242.

© 1989 B. C. Decker Inc.

pin-retained composite resin restoration replacing the mesial-incisal angle of tooth #9 (Fig. 2, A and B). The restoration was worn and stained, and marginal adaptation was poor. Replacement of the restoration was indicated.

After administration of local anesthesia, and pumicing of the tooth, a shade was selected for the new restoration. Isolation was accomplished with cotton rolls and gauze. The old restoration, including three pins, was entirely removed. A long facial bevel and a shorter lingual bevel were placed with a medium grit diamond bur (Fig. 3, A and B).

A glass ionomer liner (Vitra-Bond, 3M Dental Products Division, St. Paul, MN) was placed over the axial dentin and cured with visible light. The enamel was etched for 30 seconds with a 37% phosphoric acid gel, then rinsed and dried. A phosphonate ester dentin/enamel bonding agent (Dual-Cure Scotchbond, 3M Dental Products Division) was applied and cured according to manufacturer's instructions. A hybrid composite resin, Herculite XR shade DY (Kerr Manufacturing, Romulus, MI) was used as a "dentin replacement." The Herculite was placed to full and

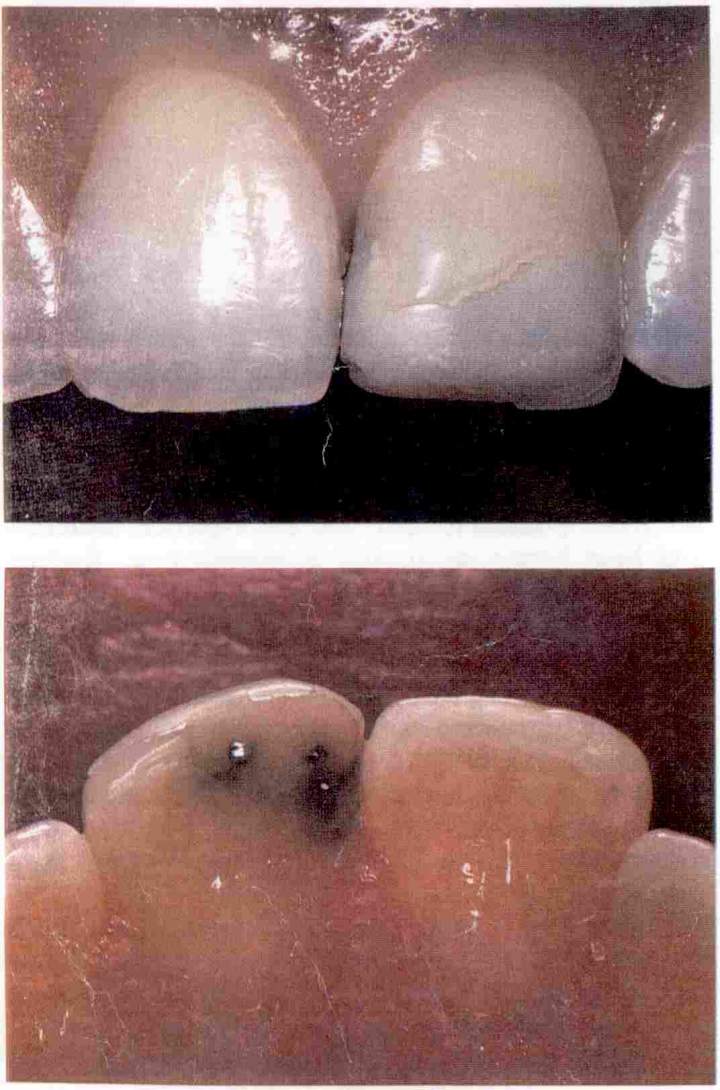

Figure 2. Facial (**A**) and palatal (**B**) views of a defective Class IV restoration.

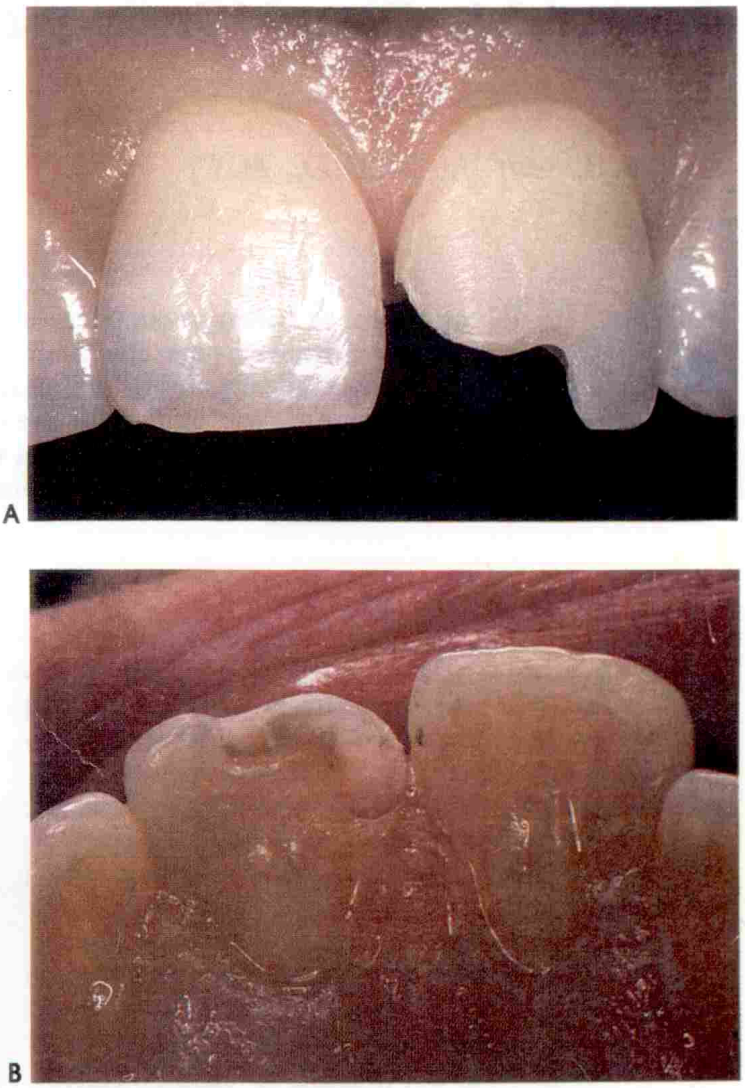

Figure 3. Facial (**A**) and palatal (**B**) views of tooth #9 after completion of preparation.

proper contour lingually and incisally to take advantage of its mechanical properties. However, this resin was kept short of proximal contact and facial contour by about 1 mm. The Herculite was cured by a 40-second exposure to a Max light (L. D. Caulk, Milford, DE) with a wide (13 mm) curing tip.

A thin layer of Silux Plus UO (3M Dental Products Division), an opaque microfilled resin, was applied over the junction of the hybrid composite with the labial enamel, and cured with visible light (Fig. 4). The final labial and proximal contours were restored using Durafill VS shade A2 (Kulzer, Inc., Irvine, CA), a translucent microfill material. Before polymerization, the resin was contoured and smoothed with a fine sable artist's brush.

Contouring of the restoration was initiated with a coarse Sof-Lex XT disc (3M Dental Products Division) and a 12-fluted carbide finishing bur. A medium grit diamond on slow speed was used for secondary anatomy (developmental grooves) and surface texturization.[7] The entire restoration was buffed with a green Polisher (Vivadent USA, Tonawanda, NY). Finally, convex areas of the restoration, i.e., line angles and labial lobes, were

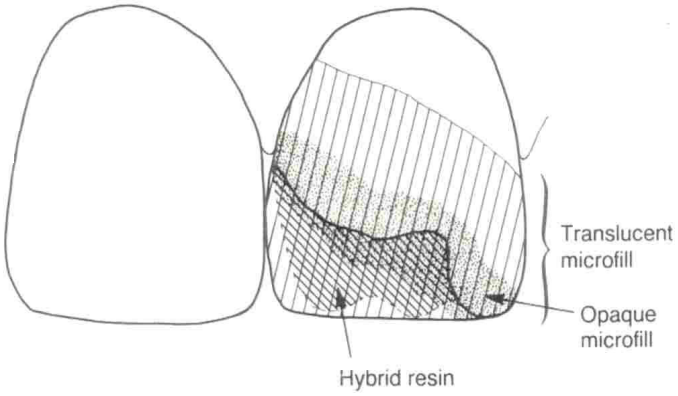

Figure 4. Diagram illustrating the combination of resin materials used in this case.

"high-shined" with a superfine XT disc. A natural, esthetic result was achieved (Fig. 5, A and B).

DISCUSSION

This paper describes a method for creating predictably esthetic Class IV restorations. A combination of composite resin materials is used in this technique. A hybrid composite is used as a dentin replacement material to give strength and internal opacity to the restoration. An opaque microfill, in a thin layer, is used to cover and hide the interface between the hybrid composite and enamel. This opaque microfill is the key to the esthetic result, because it eliminates a common problem in Class IV restorations, i.e., a line of demarcation within the restoration. Finally, a translucent microfill is used as the surface layer for its polishability and optical properties. The result is an esthetic, life-like restoration in terms of anatomy, contour, texture, and light reflectance.

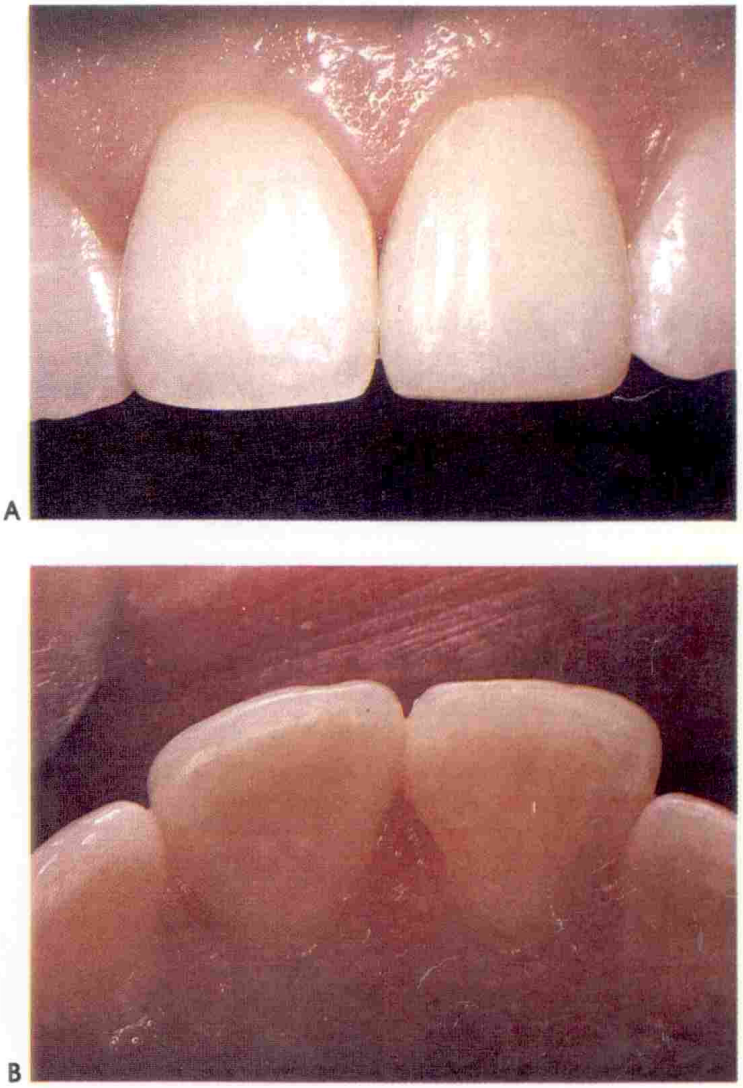

Figure 5. Facial (**A**) and palatal (**B**) views of the finished Class IV restoration in tooth #9.

References

1. Bowen RL. Properties of a silica-reinforced polymer for dental restorations. JADA 1963;66:57–64.
2. Buonocore MG. A simple method of increasing the adhesion of acrylic filling materials to enamel surfaces. J Dent Res 1955;34:849–853.
3. Cook WD, Standish PM. Cure of resin based restorative materials. II. White light photopolymerized resins. Aust Dent J 1983;28:307–311.
4. Council on Dental Materials, Instruments, and Equipment. Visible light-cured composites and activating units. JADA 1985;110:100–103.
5. Lutz F, Setcos JC, Phillips RW, Roulet JF. Dental restorative resins: types and characteristics. Dent Clin North Am 1983;27:697–712.
6. Wei SHY, Jensen M. Composite resin restoration. In: Wei SHY, ed. Pediatric dentistry: total patient care. Philadelphia: Lea & Febiger, 1988:199–203.
7. Croll TP. Simulating irregular enamel surface texture in composite resin restorations. Quintessence Int 1988; 19:311–312.