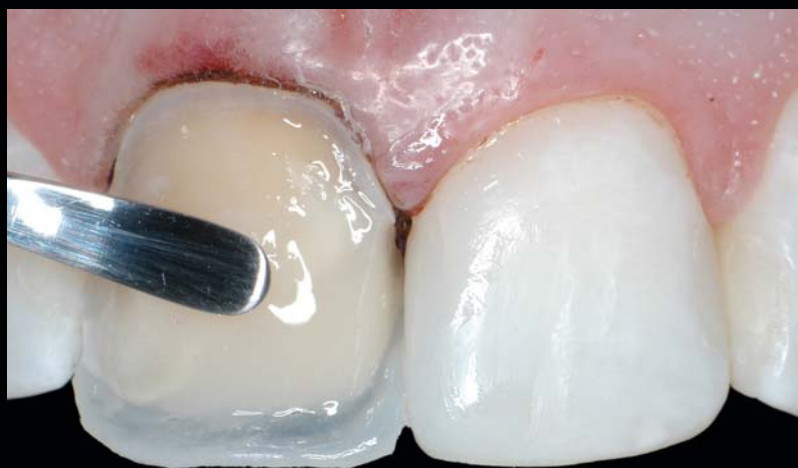

A POLYCHROMATIC COMPOSITE LAYERING APPROACH FOR SOLVING A COMPLEX CLASS IV/DIRECT VENEER/DIASTEMA COMBINATION: PART II

Newton Fahl, Jr, DDS, MS*



Restoration of a Class IV defect in the aesthetic zone in combination with a direct resin veneer can be a considerable challenge for clinicians, especially when striving to emulate the natural dentition. Shade-matching is a particular concern in achieving a natural-looking aesthetic result. Value enamels can also be used over selective areas of a Class IV restoration as needed to modify the perception of the chroma of underlying layers of artificial dentin and body enamel. This second and concluding part provides a discussion of how an advanced polychromatic composite layering technique can be used to meet the patient's aesthetic expectations.

Learning Objectives:

This article discusses how an advanced polychromatic composite layering technique is used to restore a Class IV/direct veneer/diastema. Upon reading this article, the reader should:

- Become familiar with how to properly select an opaquing agent, composite dentin, and enamel shades that elicit correct color value when performing a direct veneer on a discolored tooth substrate.
- Be able to integrate a large Class IV restoration with a direct veneer while closing a midline diastema through multilayered polychromatic stratification.

Key Words: adhesive, composite, conservative, veneer, Class IV, diastema

**Private practice, Curitiba, Brazil.*

Newton Fahl, Jr, DDS, MS, Av. Visconde do Rio Branco, 1335, Suites 23/24, 80420-210 Curitiba, Brazil
Tel: +55-41-3224-3008 • E-mail: fahl@fahl.com.br

For each patient presenting for restorative or aesthetic dental care, dental professionals strive to emulate or improve upon the natural dentition. While this can be accomplished with various direct or indirect approaches, the objective in each is to deliver a restoration capable of providing long-term function and patient satisfaction.

The key challenges when restoring a Class IV defect in conjunction with directly veneering a discolored central incisor lie in the proper selection and application of opaquing agents and restorative composites in order to produce a seamless restoration (Figure 1). The criteria for the selection of the restoratives used in the clinical protocol described herein were presented in a discussion in Part I of this article.¹

Polychromatic Composite Layering

A total-etch technique was employed on tooth #8(11), etching dentin for 10 to 15 seconds and enamel for approximately 15 to 20 seconds.² The etchant was rinsed with copious water spray; excess water was aspirated until the dentin surface presented moist. A three-step bonding agent (ie, Optibond FL, SDS Kerr, Orange, CA) was applied as per the manufacturer’s directions and light cured (Figure 2).

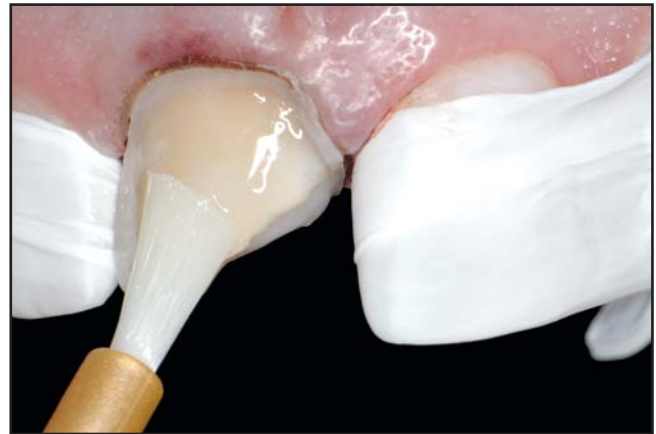

Figure 2. A hydrophilic bonding agent is applied as per the manufacturer’s directions and light cured.

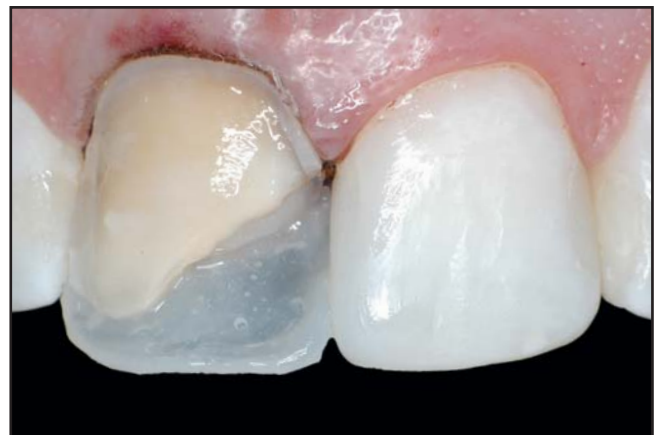

Figure 3. An increment of resin (ie, shade T3) is used as a “lingual shelf.” All excess that extrudes off is removed and the lingual shelf is light cured.

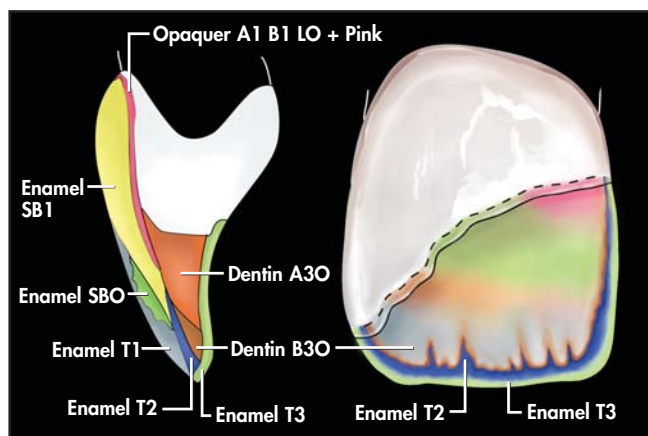


Figure 1. Artificial body enamel, artificial dentin, and artificial effect enamel shades, respectively, were selected to compose the strata of the polychromatic restoration. A color map was produced to aid during the restorative stage.

A 0.3-mm-thick layer of resin (ie, shade T3) was used as a “lingual shelf” to establish the palatal contour, proximal contact, and incisal edge position. It was initially applied onto the matrix, which in turn was pressed against the palatal aspect of the adjacent dentition. All excess that extruded off was removed, and the lingual shelf was light cured in position for 20 seconds from the labial aspect. Any uncured material on the palatal aspect was cleaved off with a curette; further exposure to light followed in order to ensure thorough polymerization. This maximized the potential for attaining a successful restoration from a color and form standpoint, as it became easier for the clinician to visualize the thickness and

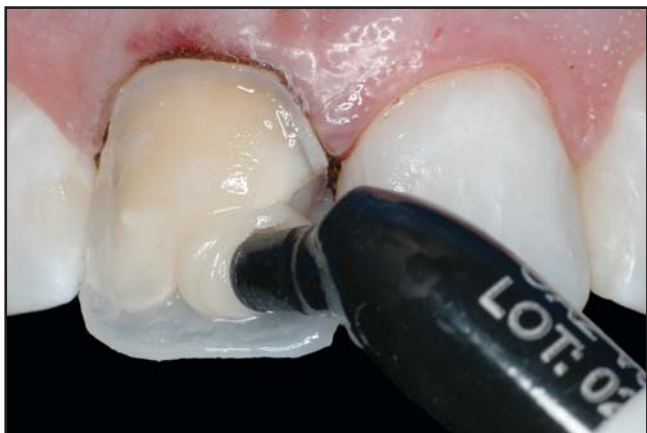

Figure 4. A higher chroma (ie, shade A2-0) artificial dentin (ie, Venus, Heraeus Kulzer, Armonk, NY) is applied onto the lingual shelf.

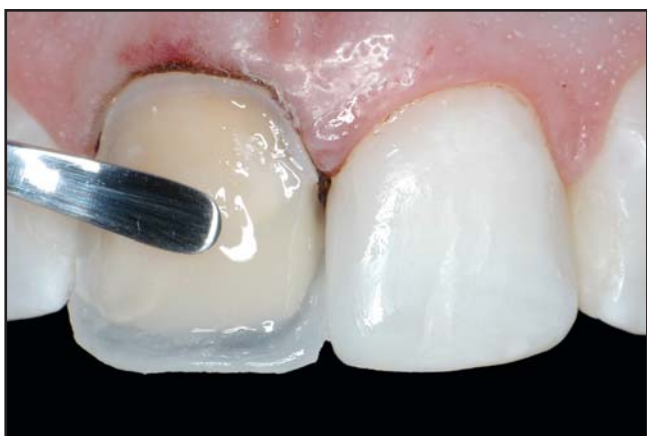

Figure 5. The artificial dentin extends over the Class IV bevel. This increment should accommodate room for the application of the dentin mamelon effects.

boundaries of each subsequent increment of composite. As a marked halo effect was desired, T3 was sculpted to a thicker volume facially along the incisal edge, thereby creating an opalescent trait (Figure 3).

As a chroma variance was perceived at the shade-selection phase, two artificial dentin shades were selected to impart the chroma gradient desired. A higher chroma artificial dentin (ie, shade A2-0) was applied onto the lingual shelf, which determined the showing-through of a deeper, warmer color from within (Figure 4). The artificial dentin (ie, shade A2-0) was carried over the bevel preparation to about half of its length. Due to the natural optical characteristics of the selected microhybrid

resin (ie, Venus, Heraeus Kulzer, Armonk, NY), the fracture line was nearly concealed at this stage. This increment was placed approximately 1.5 mm short of the facio-incisal line angle to allow room for the application of dentin mamelons (Figure 5). Microhybrid resin (ie, shade B2-0) was applied over the incisal portion of the first layer of artificial dentin and sculpted in the shape of mamelons, as per the anatomic details perceived during the shade-selection stage (Figure 6).

As a first veneering layer, an opaquer agent was applied over the discolored dentin substrate to elevate the value of the prepared tooth structure to match that of tooth #9. A 5:1 mix of Creative Color Opaquer A1-B1-LO and Pink (Cosmedent, Inc, Chicago, IL) was used to achieve this goal. The mix ratio can vary according to the degree of discoloration of the substrate to be veneered. As the pink opaquer aids in neutralizing gray tones and is highest in value, its proportion with the other opaquer shade must be experimented with beforehand to ascertain the correct value change without making it overly bright. To best evaluate the change in value, black-and-white digital photographs were taken during the application of the opaquer until the correct value was obtained (Figure 7). Multiple thin wash layers were applied, light cured, and compared with the color

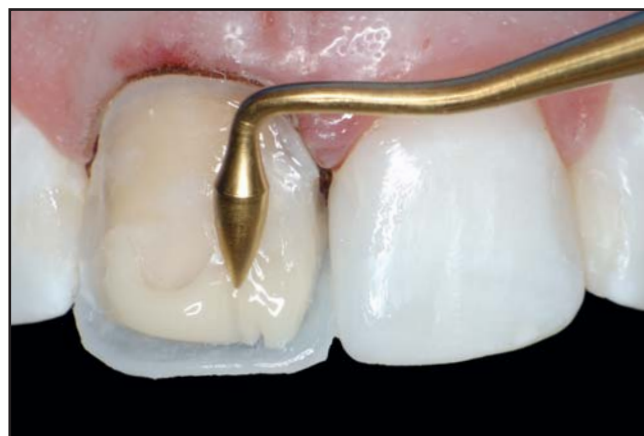

Figure 6. Using a fine-tipped composite instrument, resin (ie, shade B2-0) is applied to the restoration. A fine-tipped #1 brush is used to refine the mamelon morphology.

mock-up until approximately 80% to 85% of the desired final value was achieved. An artificial enamel translucent effect (ie, shade T2), which bore a bluish hue, was inserted into the mamelon depressions and slightly over the incisal portion of the artificial dentin and was light cured. Care was taken not to over-apply a translucent effect enamel shade, which could have rendered a low value where it had been layered (Figure 8).

An artificial body enamel of the final desired shade (ie, SB1) was applied to the cervical one third and feathered over the middle one third and slightly covered the incisal one third. The primary objective for the body enamel was to achieve the final hue and chroma of the restoration, although a further elevation of the value was also part of the goal. Thus, this layer was brought to full contour cervically, phasing out towards the middle and incisal one thirds (Figure 9). As white spots had been color mapped during shade selection, it was decided to reproduce them by the application of a higher opacity/higher value shade (ie, SBO) on the restoration to attempt to achieve symmetry between the two central incisors (Figure 10).

The final layer was a value-and-chroma-modifying effect enamel (T1). A mylar strip was placed interproximally and pulled through to aid in creating a tight contact and correct facial embrasure forms. Primary anatomy was established with contouring instruments and brushes, and a final 40-second cure was effected (Figures 11 and 12).

Finishing and Polishing

Coarse-gritted finishing discs (ie, Sof-Lex Pop On XT, 3M Espe, St. Paul, MN) were used to produce the primary anatomy of tooth #8, thereby establishing symmetrical light-reflecting and light-deflecting zones determined by placement of transitional labio-proximal line angles. Fine and superfine finishing diamond burs (ie, #F889 and #SF889, Newton Fahl Anterior & Posterior Finishing Logic Set, Axis Dental, Irving, TX) were used to bring the finishing margins to a flush contour with the peripheral enamel substrate.³ Secondary and tertiary

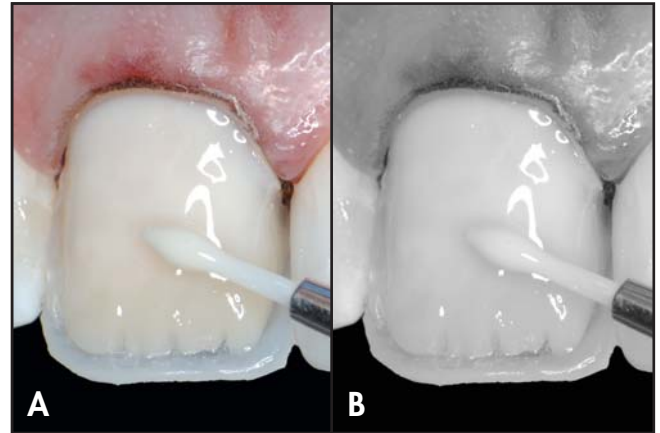


Figure 7A. An opaquing agent is applied over the discolored dentin substrate to match the value of tooth #9(21). **7B.** Black and white photography is used for precise value determination.

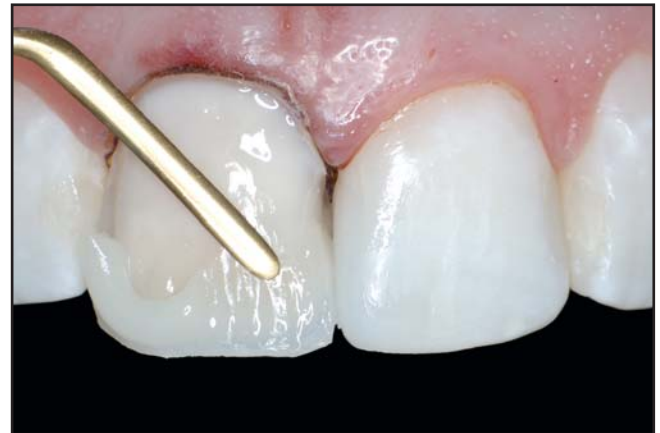

Figure 8. A translucent effect is inserted into the mamelon depression to impart a somewhat translucent band mesiodistally.

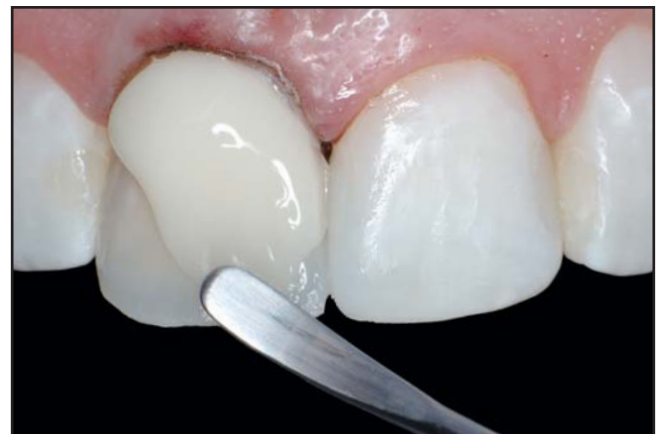

Figure 9. An artificial body enamel of the final desired shade is applied to the cervical one third and feathered over the middle and incisal thirds.

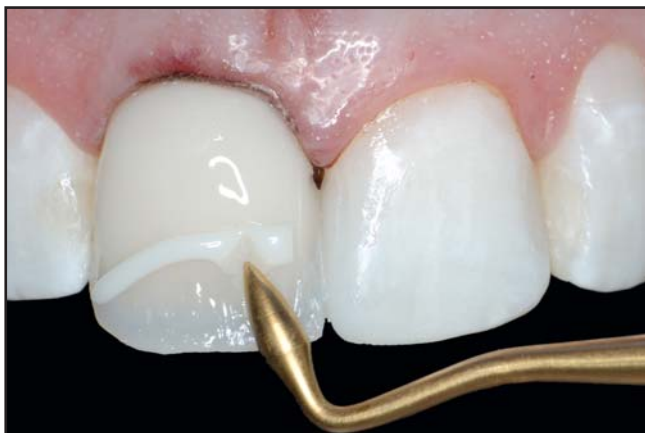

Figure 10. White spots (ie, shade SBO) noted during shade selection are reproduced to achieve symmetry between the central incisors.

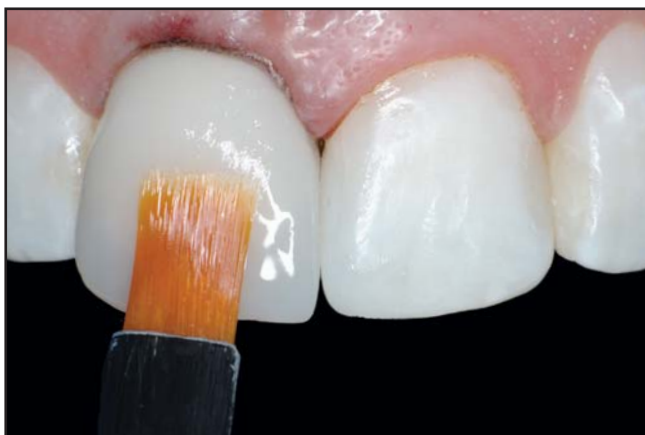

Figure 11. The final resin layer is a value-modifying effect enamel. It can partly conceal the underlying halo, mamelon, translucent, and related effects.

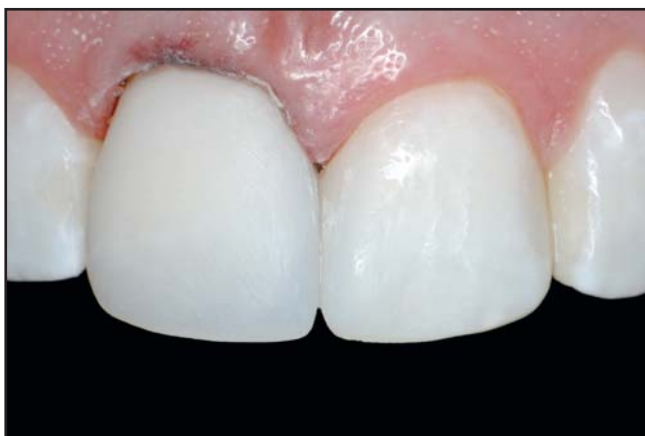

Figure 12. Finishing discs are used to achieve the geometric form and correct transitional line angle placement.

anatomies were accomplished with a fine-grit, flame-shaped finishing diamond bur (ie, #F888, Newton Fahl Anterior & Posterior Finishing Logic Set, Axis Dental, Irving, TX) on a 1:4 low speed increaser (ie, 2325LN, Kavo, Lake Zurich, IL) for better operative control (Figure 13). A silver powder was applied onto the surfaces of both central incisors to help visualize the light-reflective and light-deflective areas, as well as secondary and tertiary anatomy, and further morphological corrections were ensued. Diamond finishing strips (ie, FlexiDiamond, Cosmedent, Chicago, IL) and plastic strips (ie, Epitex, GC America, Alsip, IL) were used for refining and polishing the interproximal areas. Extraneous texture was removed by gentle buffing of the restoration with rubber points and wheels (ie, PoGo, Caulk-Dentsply, York, PA) until the surface anatomy that mimicked the contralateral tooth had been achieved. An aluminum oxide polishing paste (ie, Enamelize, Cosmedent, Chicago, IL) was used on a felt buffing disc to polish into the striations created with the finishing bur and to bring the restoration to a final natural gloss. Examined postoperatively, favorable integration of form and color were evident, particularly when contrasted with the color mock-up tab used as a reference from the beginning of the procedure (Figures 14 and 15).

Discussion

There is no set rule for establishing the right value when selecting opaques because each system bears varying percentages of oxides, which causes the opaquing agent to become of greater or lesser light reflectance. The clinician should resort to black and white photography to ascertain the changes in value during the opaquer application phase. As all that is seen with a black and white photograph is the value (ie, gray scale) of Munsel's three-dimensional color system, it becomes more predictable to visualize results if hue and chroma are eliminated altogether. The natural dentition dehydrates during the restorative phase and the value is elevated, thus making it impossible to relate to

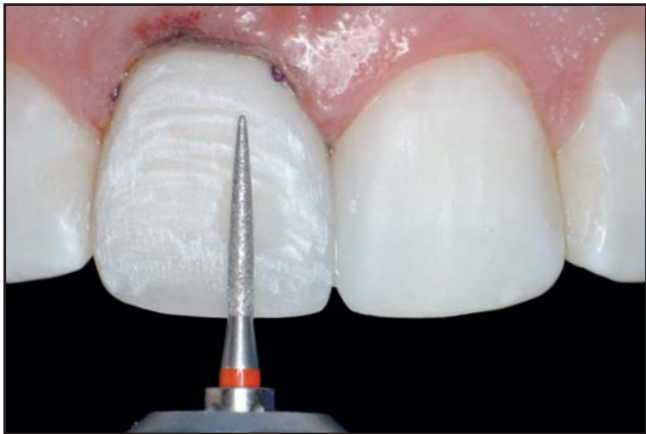


Figure 13. Fine and superfine, fine-tipped finishing diamond burs are used to contour the peripheral enamel substrate.

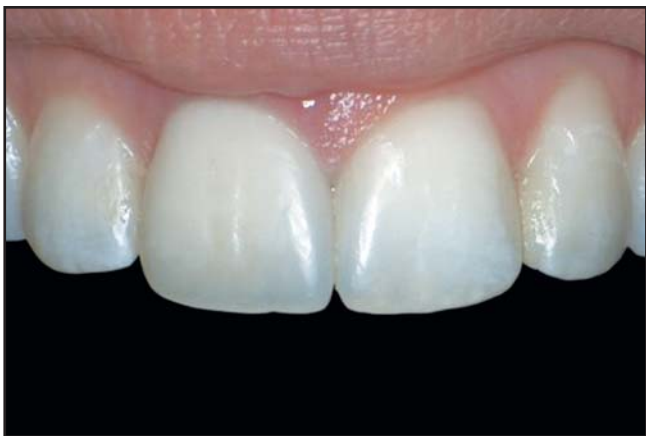

Figure 14. A 30-day postoperative view demonstrates a favorable integration of form and color.

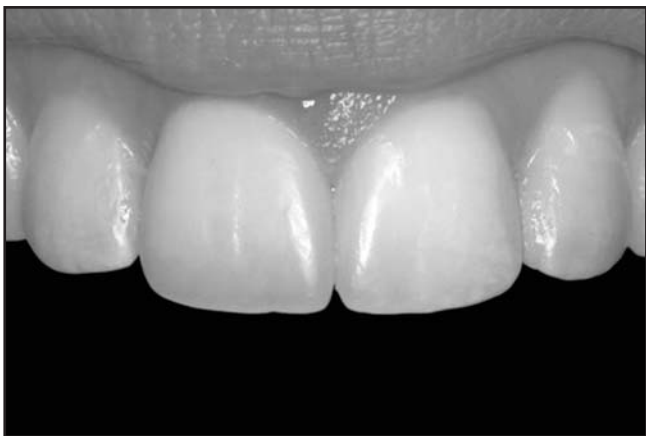

Figure 15. The attainment of correct color value is evident through black and white photography.

the adjacent teeth for value check. The color mock-up used for initial shade assessment and material selection should be used for achieving correct value at this point. There would be no change in any of the three dimensions of color due to the stability of the composite.

Regarding artificial enamel selection, value enamels can usually be of high, medium, or low intensity and its selection will depend upon the brightness and degree of translucency/opalescence that is intended over the lobe areas and incisal one third. It may conceal the underlying halo, mamelon, translucent, and characterization effects to a greater or lesser degree depending on how much of it the clinician desires to be shown. Value enamels can also be used over selective areas of the Class IV/veneer restoration as needed to modify the perception of chroma of underlying layers of artificial dentin and body enamel.

Conclusion

Composite resins remain one of the most important tools in the clinician's armament. Such systems can provide reliable strength and a realistic aesthetic result. Part I of this discussion presented a technique available to skilled clinicians to meet patients' expectations through the utilization of a direct composite resin and partial closure of a midline diastema on the maxillary central incisor. This concluding part presented a means for restoring a Class IV/direct veneer defect in the aesthetic zone.

Acknowledgment

The author declares that he receives financial compensation from Axis Dental for the sale of the Newton Fahl Anterior & Posterior Finishing Logic Set.

References

1. Fahl N Jr. A polychromatic composite layering approach for solving a complex class IV/direct veneer-diastema combination: Part I. *Pract Proced Aesthet Dent* 2006;18(10):641-645.
2. Fahl N Jr. The direct/indirect composite resin veneers: A case report. *Pract Periodont Aesthet Dent* 1996;8(7):627-638.
3. Croll TP. Simulating irregular enamel surface texture in composite resin restorations. *Quint Int* 1988;19(4):311-312.