

Protocol For Predictable Restoration Of Anterior Teeth With Composite Resins

Newton Fahl, Jr., CD, MS

Gerald E. Denehy, DDS, MS

Ronald D. Jackson, DDS

The composite resins have reached a high degree of excellence and are now utilized with predictable results in restoring the anterior dentition. This article discusses the development of these resins and the histologic and optical considerations (polychromatic characteristics, hue, translucency and opacity, chroma, value, strength, and polishability). In restorative materials, the use of universal or all-purpose restorative resins is considered, ie, materials that combine the functional strength necessary for the posterior regions and the high gloss polishability necessary to emulate enamel in the anterior. The restorative sequence of cervical, middle, and incisal thirds describes the materials best suited for each third, along with aids to create the intricate refinement of hue, chroma, and value. The learning objective of this article is to review the principles involved in these restorations and to provide a protocol for their clinical implementation.

In the past, clinicians were reluctant to use composite resins in larger anterior tooth build-ups due to the less-than-desirable properties of the earlier generation.¹ Composite resins were usually introduced in kits that contained a poor selection of shades and frequently only one degree of opacity. The resins lacked color stability, wear resistance, polishability, and sculptability — char-

acteristics required to make them the material of choice. These limitations led many clinicians to select all-porcelain jackets or porcelain-fused-to-metal crowns in order to achieve maximum aesthetics and strength. The aesthetics of a crown, fabricated by a highly skilled technician, could not be rivaled by any directly placed restorative material. In the laboratory, the hue, chroma, and

level of polishability that rivals that of glazed porcelain and dental enamel.² In addition, there are commercially available products that present varying degrees of opacity³ as required for the different areas of a tooth. Finally, the research conducted on the adhesive materials indicates a promising future where the clinician will pass from "amputation to augmentation dentistry."⁴ This article presents a procedure for restoration of the anterior teeth, regardless of the defect classification.

Dr. Fahl, Jr. maintains a private practice, emphasizing Restorative and Aesthetic Dentistry, in Curitiba, Brazil. He lectures internationally and conducts continuing education seminars on Aesthetic Dentistry in Brazil and other South American countries.

Dr. Denehy is Professor and Graduate Program Director, Department of Operative Dentistry, College of Dentistry, University of Iowa, Iowa City, IA. He also maintains a part-time private practice, emphasizing Restorative and Aesthetic Dentistry, in Iowa City, IA.

Dr. Jackson is a faculty member, Post-graduate Program of Aesthetic Dentistry, SUNY, Buffalo, NY, and Baylor College of Dentistry, Dallas, TX. He maintains a private practice, emphasizing Restorative and Aesthetic Dentistry, in Middleburg, VA.

Address correspondence to:

Newton Fahl Jr., DDS, MS
Av. Candido de Abreu, 526-1606/B
80530-905 Curitiba, PR
Brazil

Tel: 011-55-41-254-4338
Fax: 011-55-41-252-3749

The physical properties
of the composite resins
have reached a high level
of excellence ...

value could be so well harmonized with the adjacent teeth that the final restoration frequently could not be distinguished by the eye of the beholder.

Today, the physical properties of the composite resins have reached a high level of excellence, and the restorative dentist can have confidence in the aesthetics and longevity of the results. The newer formulations of particle size and distribution have imparted additional strength and varying degrees of polishability, allowing the use of composite resins in rather high stress-bearing areas and concomitantly providing a

HISTOLOGIC AND OPTICAL CONSIDERATIONS

A natural central incisor is used to illustrate the clinical procedure. Horizontal and vertical imaginary lines are drawn along the thirds of the clinical crown for the purpose of compartmentalizing the surface area (Figure 1). A sagittal section is appropriate for assessing enamel and dentin thicknesses (Figure 2).

POLYCHROMATIC CHARACTERISTICS

A variation in hue, chroma, and value renders the tooth polychromatic. When the facial aspect of the anterior dentition is thoroughly examined, the tridimensional color system of Munsell⁵ is readily perceived. Even though monochromatic teeth are found, polychromatic nuances are generally thought to be

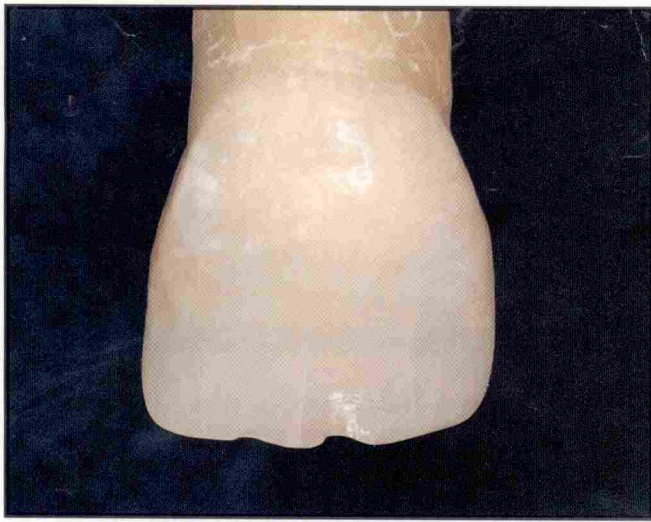

Figure 1. Facial view of the maxillary central incisor — natural color.

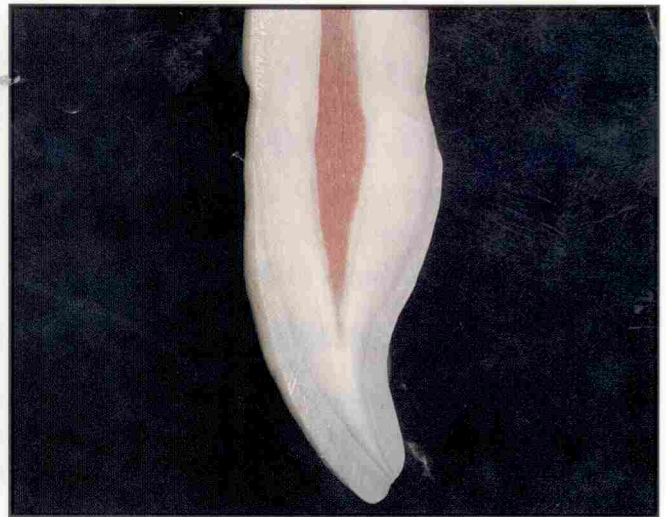

Figure 2. Sagittal section of a maxillary central incisor with light reflecting through it, exhibiting different translucencies and opacities.

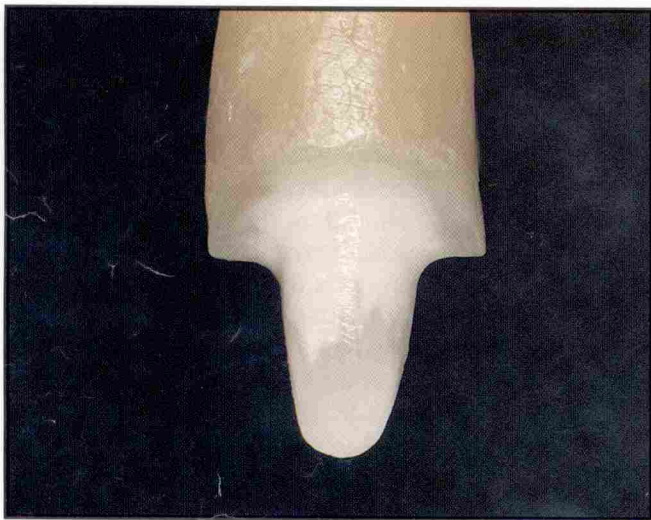


Figure 3. Maxillary central incisor with accentuated butt shoulder preparation — buccal aspect.

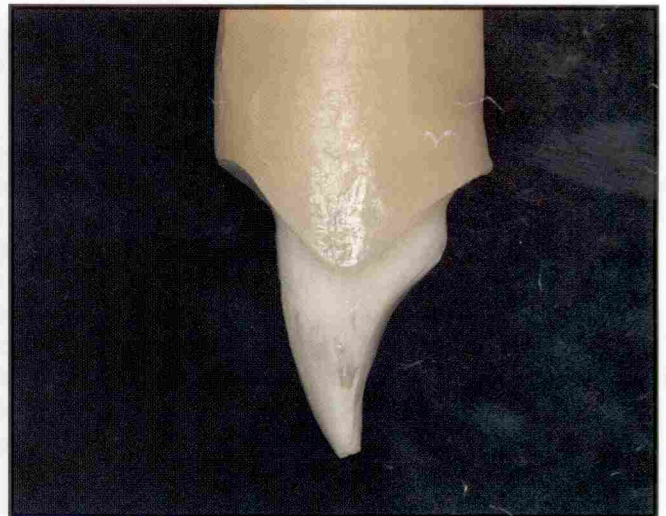

Figure 4. Maxillary central incisor with accentuated butt shoulder preparation — proximal aspect.

more attractive to the aesthetic eye. Sometimes a fourth color dimension can be encountered, as described by Muia.⁶ When evaluating the polychromatic characteristics of a tooth, age factors should also be taken into account and will reveal variations in chroma (higher), value (lower), and probably in hue.⁷ Frequently, the translucency is also higher.

As the standard for the didactic purposes of this article, a young tooth is considered; the principles outlined can be extrapolated to middle-age and elderly dentition. Subtleties in color variation — generally not perceived from a conversation distance — are perhaps one of nature's greatest wonders and have become a challenging objective when restoring the anterior teeth with fidelity.

HUE

The same hue is frequently found at the cervical and middle thirds. Because of the way light is reflected, refracted,

The newer formulations of particle size and distribution have imparted additional strength and polishability ...

absorbed, and transmitted, distinct hues can be seen at the incisal third. Around the dentinal mamelons and extending to the proximal aspects towards the

middle third, predominantly bluish or grayish hues (or a mixture thereof) are projected, imparting a beautiful and youthful characteristic. Maverick colors along the tip of the mamelons, as well as white hypoplastic spots and mottled enamel, may also contribute to an aesthetic hue variation at the incisal middle third.

TRANSLUCENCY AND OPACITY

The sagittal section (Figure 2) presents the dimension of translucency and opacity. Muia⁶ states that it is the dentin that imparts all of the color of a tooth, with the exception of the maverick colors which usually are present within the enamel matrix. The enamel is but a fiberoptic structure that conducts light

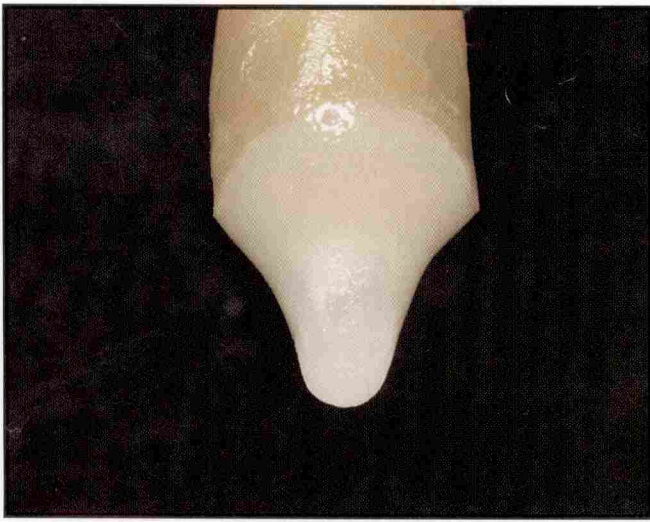

Figure 5. Opaque microfill applied onto the cervical third — buccal aspect.

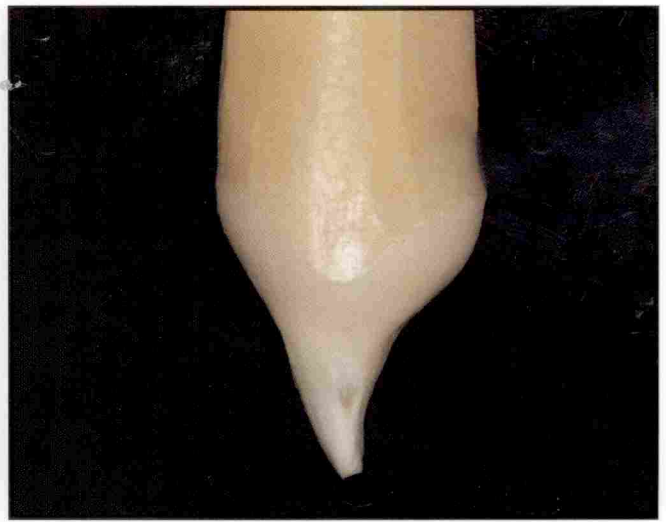

Figure 6. Opaque microfill applied onto the cervical third — proximal aspect.

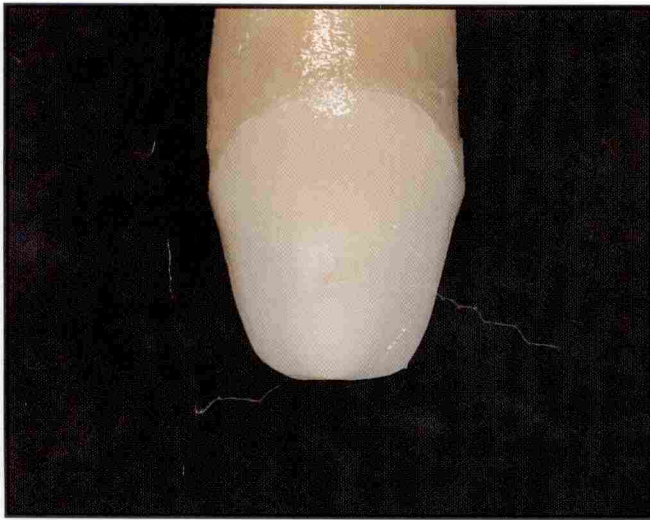


Figure 7. Artificial dentin — hybrid composite core — buccal aspect.

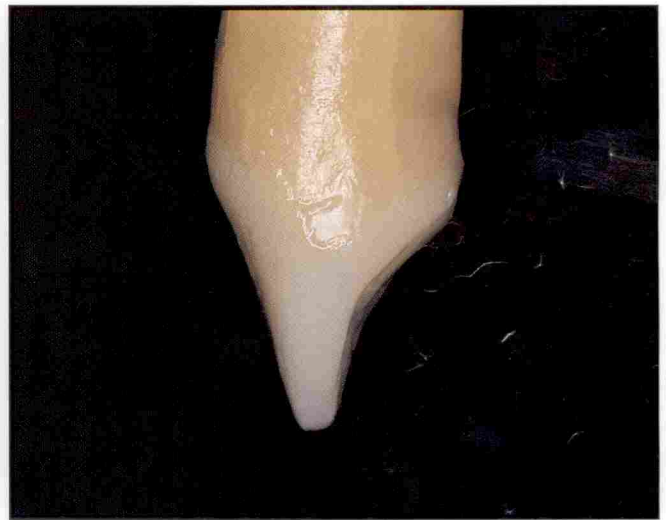

Figure 8. Artificial dentin — hybrid composite core — proximal aspect.

through its rods to capture the color of the underlying dentin. Therefore, a decrease in dentin thickness from the cervical third (the thickest) to the incisal third (the thinnest) will automatically result in a decrease in opacity. Conversely, an increase in enamel thickness from the cervical third (the thinnest) to the incisal third (the thickest) will enhance the translucency.⁸

CHROMA

Since the dentin decreases in thickness from the cervical to the incisal third, the saturation also decreases. A hue-diluting effect (chroma variation) can be seen in most cases, even if subtly. For restorative purposes, it could be stated that the chroma of the cervical third is one degree higher than that of the middle

third. For instance, if the basic shade selected for the middle third is A2, that of the cervical third should be A3; if B1, then B2, etc.

**... polychromatic nuances
are generally thought to
be more attractive to
the aesthetic eye.**

VALUE

Value is perhaps the most important of all three color dimensions.⁹ The variation in hue, chroma, and degrees of opacity

is responsible for a variation in value along the crown. Normally, a higher chroma (more saturated hue) will elicit a lower value (darker). More opacious areas of greater opacity will show a higher value, whereas more translucent areas will show lower values because they reflect light wavelengths that contain more gray and blue hues. Since a higher chroma is usually found in the cervical third, the value is slightly lower than that of the middle third. The incisal third presents the lowest value of the three thirds.

RESTORATIVE MATERIAL CONSIDERATIONS

In addition to the principles discussed, a comprehensive knowledge of composite resins and their individual properties is

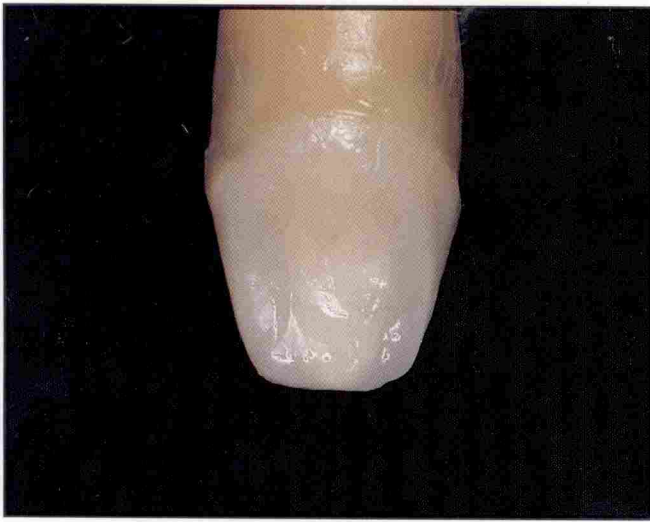

Figure 9. Artificial enamel — hybrid composite core — palatal aspect.

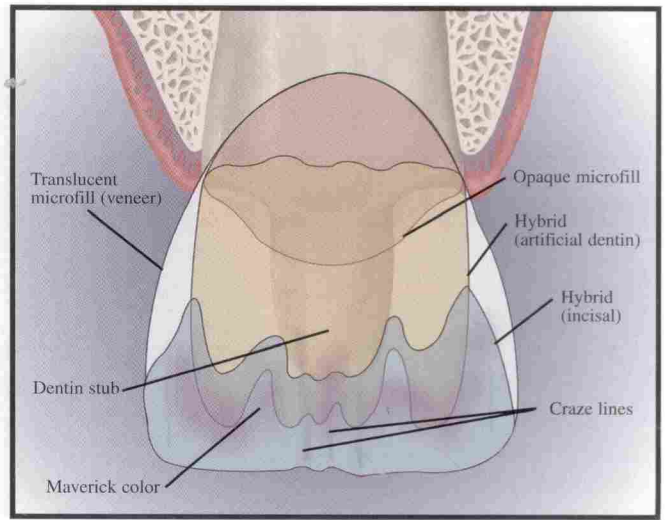


Figure 10. Three-dimensional color diagram exhibiting the different layers of the restorative resins — buccal aspect.

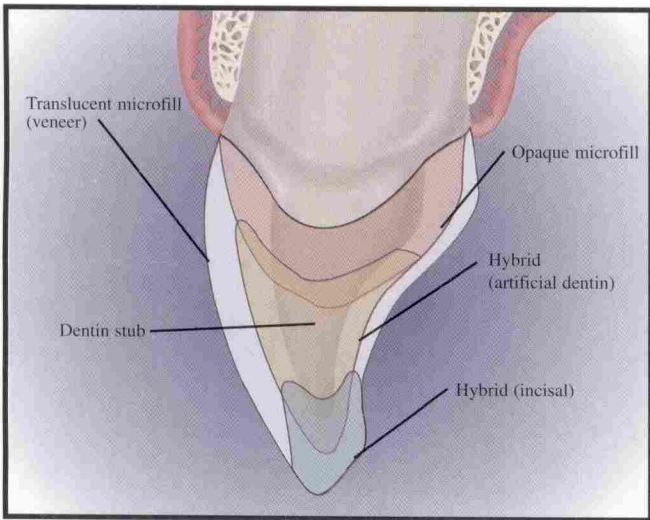


Figure 11. Three-dimensional color diagram exhibiting the different layers of the restorative resins — proximal aspect.

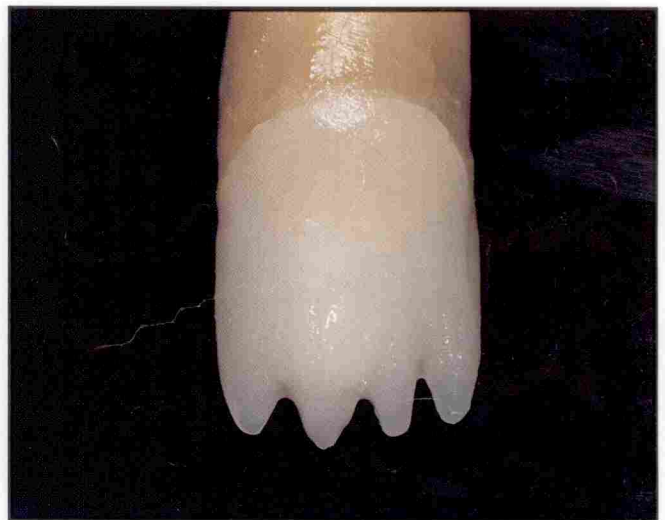

Figure 12. Artificial dentin — hybrid composite core (initial shape of mamelons) — buccal aspect.

necessary in order to properly restore the anterior dentition. Since the introduction of visible light cured composite resins in the early 1970s,¹⁰ numerous formulations with varying physical properties have become available. Along with the improved quality of each newly-introduced material has sometimes come confusion on the part of clinicians, who may be unaware of which resins would be best suited to their needs.

The materials have come a long way from the early macrofills to the state-of-the-art microfills and microhybrids. Many freehand bonders believe in all-purpose restorative resins — resins that will impart the resistance necessary to withstand shear stresses of the posterior

region and the high gloss needed to mimic enamel. These two characteristics seem to be the primary prerequisites in the ultimate composite resin.

The authors still find it necessary to use different resins bearing different physical properties for the various areas of the tooth.

Unfortunately, such a composite resin still remains to be developed. Microhybrids have enough resistance for most stress-bearing areas in the anterior

segment of the arch, and the initial polish may equal that of a microfill, depending on the polishing materials used. However, they are neither capable of maintaining nor enhancing their high gloss with time, as do the microfills. Therefore, the authors still find it necessary to employ different resins bearing different physical properties for the various areas of the tooth, as outlined in the following sequence.

RESTORATIVE SEQUENCE

Each third of the tooth is restored with a composite resin according to the principles of hue, chroma, value, opacity, translucency, strength, and polishability necessary for each area. A prepared natural central incisor is used to illustrate the sequence (Figures 3 and 4).

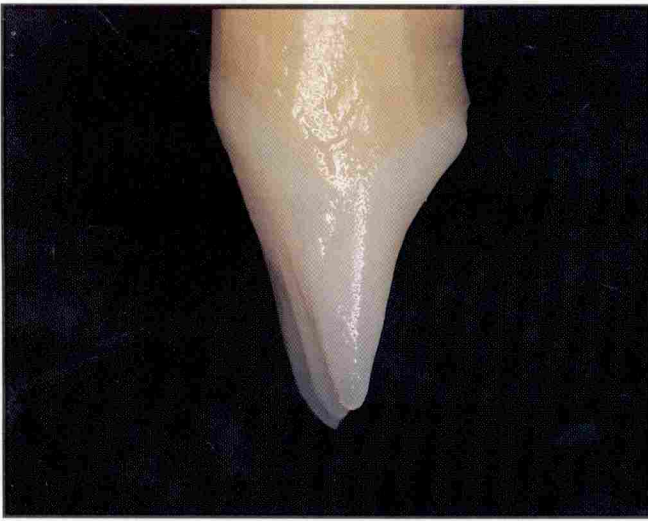

Figure 13. Artificial dentin — hybrid composite core (initial shape of mamelons) — proximal aspect.

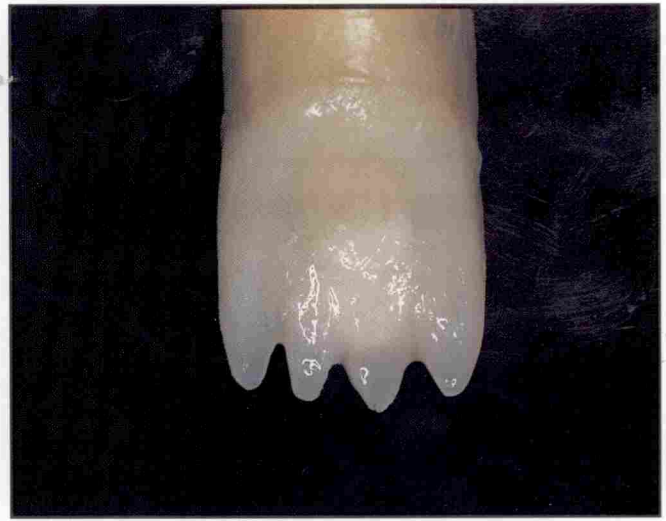

Figure 14. Artificial dentin — hybrid composite core (initial shape of mamelons) — palatal aspect.

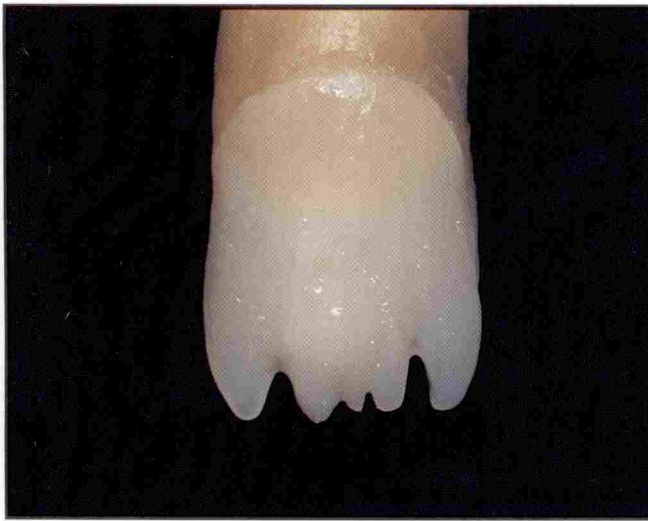

Figure 15. Artificial dentin — hybrid composite core (final shape of mamelons) — buccal aspect.

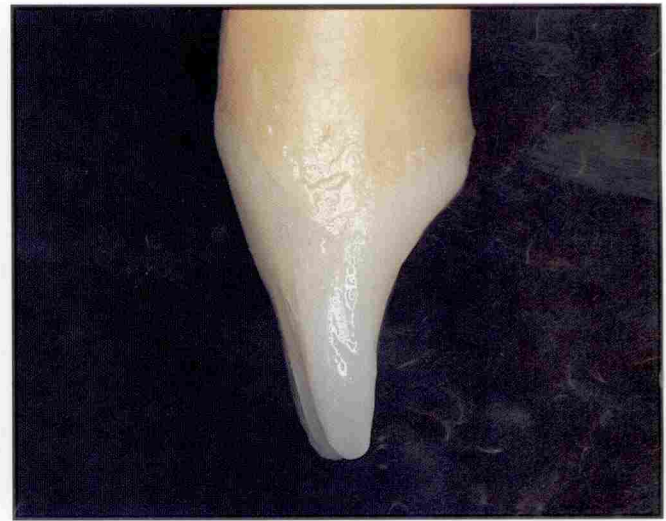

Figure 16. Artificial dentin — hybrid composite core (final shape of mamelons) — proximal aspect.

CERVICAL THIRD

A composite resin with a certain amount of resiliency is required for this area to withstand the flexural stresses that increase during function.¹¹ A more highly filled composite will probably lead to marginal breakdown with subsequent leakage.¹² A combination of higher opacity and intensified chroma is another characteristic to be considered. Finally, a resin that will impart the best polishability should be the material of choice. When all of these requirements are fulfilled, the end result is an opaque, highly saturated, microfilled composite resin (Figures 5 and 6). From among the brands available, a particular brand (eg, Silux Plus Opaque, 3M, St. Paul, MN; Heliomolar, Vivadent, Amherst, NY)

fulfills all the requirements and is highly sculptable. Alternatively, a small amount of opaque or tint covered with a microfill can achieve a comparable effect (eg,

A composite resin with a certain amount of resiliency is required for the cervical third ...

Creative Color and Renamel Microfill, Cosmedent, Chicago, IL; Kolor Plus, Kerr, Glendora, CA; Durafil VS, Heraeus Kulzer, Irvine, CA).

MIDDLE THIRD

In this area, there is a need for increased strength. Shear forces are of greater magnitude, and a restorative resin, bearing high cohesive strength, is indicated.¹¹ There can be a very slight increase in translucency at the middle third when compared with the cervical third, although this is not true in every situation. Therefore, a resin combining strength and diverse degrees of opacity should be used as the core, body, or “artificial dentin” of the restoration (Figures 7 through 9). Among today’s composite formulations, the hybrids and/or microhybrids are the resins which are best suitable for the core of the restoration. Due to the similarities in optical properties they share with

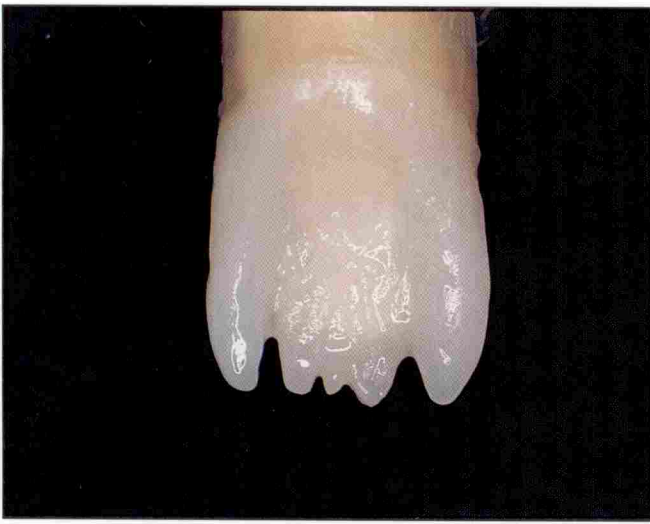

Figure 17. Artificial dentin — hybrid composite core (final shape of mamelons) — palatal aspect.

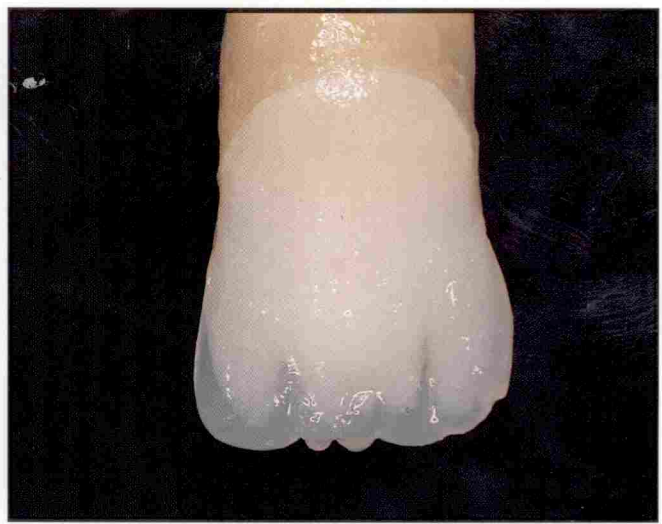

Figure 18. Artificial dentin — hybrid composite core (translucent incisal resin) — buccal aspect.

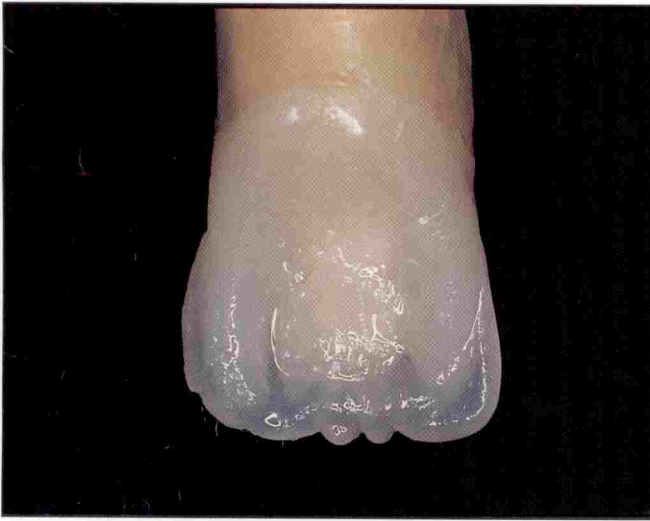

Figure 19. Artificial dentin — hybrid composite core (translucent incisal resin) — palatal aspect.

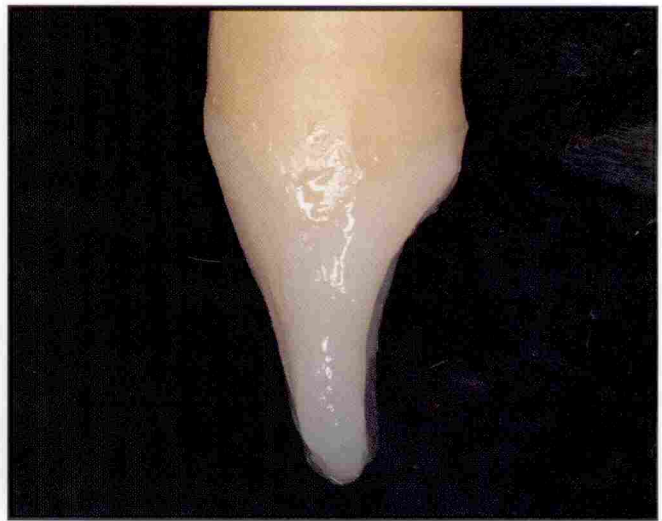

Figure 20. Artificial dentin — hybrid composite core (translucent incisal resin) — proximal aspect.

dentin, hybrids and microhybrids can mimic natural dentin quite well. A chroma one tone darker than the final desired shade should be used for this reconstructive step. Many fine resins are available for the artificial dentin build-up (eg, Herculite XRV dentin and enamel shades, Kerr, Glendora, CA; Z100, 3M, St. Paul, MN; Renamel Hybrid, Cosmedent, Chicago, IL; Amelogen Universal Opaque, Ultradent, South Jordan, UT; Tetric, Vivadent, Amherst, NY).

The shape of the artificial dentin should equal that of the natural dentin after a complete enamel demineralization. The outermost boundaries of the artificial dentin should not exceed the projected dento-enamel junction (DEJ) of the tooth, leaving a space for

a layer of “artificial enamel” (Figures 10 and 11). The final layer must be of a microfilled composite resin whose characteristics should resemble those

**Increased strength is required
in the middle third,
since the shear forces are
of greater magnitude ...**

of the natural enamel. There is a need for more translucency here than that given by the opaque microfill used on the cervical third. Yet, the resin must

be capable of imparting the final blocking shade (usually with a lower chroma) to the restoration, without totally blocking out the reflection of the underlying hybrid. The final desired shade must be achieved with the “artificial enamel” resin. To produce a life-like restoration, polishability is once more necessary at the outer surface of the restoration. Freehand bonding relies on the artistry of sculpting composites into a precise anatomic shape with the aid of spatulas and brushes, not merely on confining a disorganized mass of resin into a preformed matrix before polymerization. Therefore, sculptability is another absolutely essential property that must be present in a microfill. For the artificial enamel layer, the authors provide

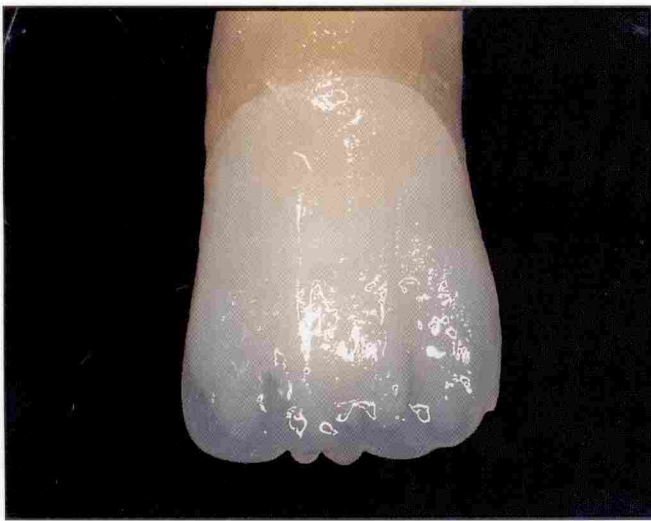

Figure 21. Incisal third characterization — blue, gray, or lavender tints applied to accentuate translucency.

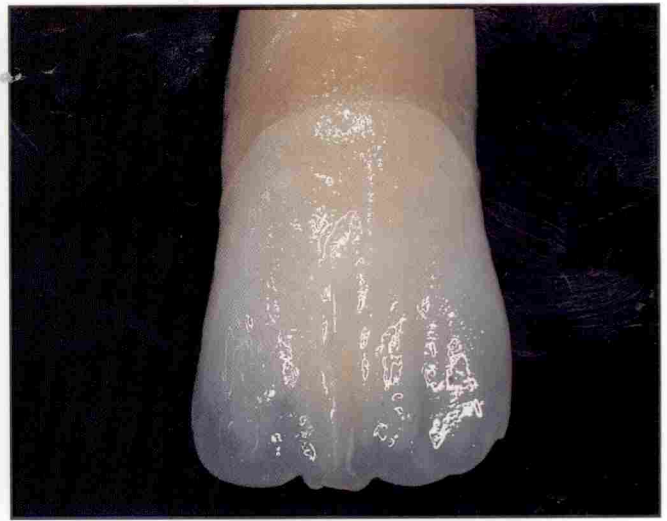

Figure 22. Incisal third characterization — tints and opaquers applied to achieve maverick colors.

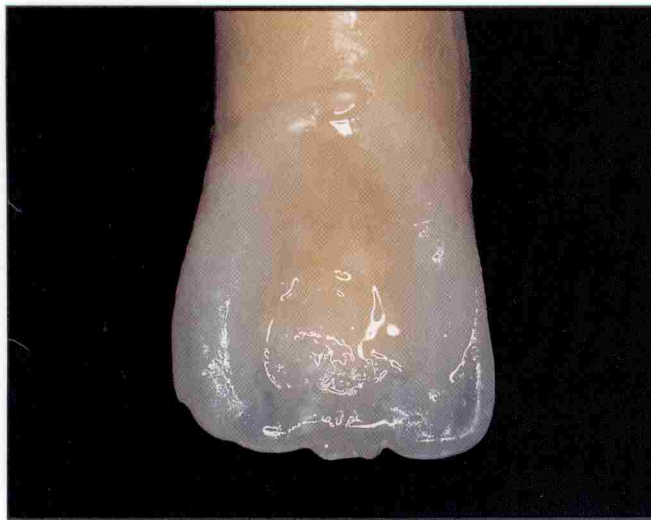

Figure 23. Incisal third and palatal fossa characterization — tints and opaquers applied to achieve maverick colors.

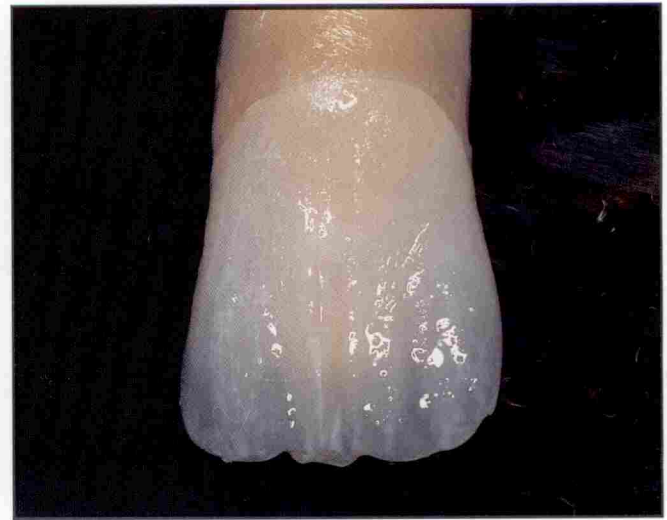

Figure 24. Incisal third characterization — tints and opaquers applied to achieve maverick colors.

their recommendation (Durafill VS, Kulzer, Irvine, CA; Renamel, Cosmesdent, Chicago, IL; Amelogen Microfil, Ultradent, South Jordan, UT; Heliomolar, Vivadent, Amherst, NY).

INCISAL THIRD

Of all three thirds, the incisal third is perhaps the one that presents the most serious challenge, because perception of the multiple variations in hues, chromas, and values is necessary in addition to the intricacy of anatomic details, to precisely reproduce the natural dentition. Since this area has to withstand the greatest stress of all, it is imperative that a composite resin with high fracture resistance be used. In addition to strength, a high degree of translucency is necessary between

and around the mamelons, which may vary from imperceptibility to accentuated dentin elongations of distinct polychromatic effects (Figures 12

**Sculptability is another
absolutely essential property
that must be present
in a microfill.**

through 17). Hybrids are usually the best restorative material for this area. Shades in the darker range (higher chroma) are required for the mamelon

build-ups; some commercially available kits also carry one or more incisal shades. Some incisors tend to project a gray-blue hue and others a white hue. The resistance of incisal hybrid should encompass the incisal and proximal aspects (Figures 18 through 20). The incisal third can at times be so diversified in terms of polychromatic nuances that the aid of tints and opaquers is necessary to mimic a natural tooth. These aids allow the creation of an intricate refinement of hue, chroma, and value. Blue, gray, or lavender tints should be used to accentuate an intrinsic translucent effect, and they should be used sparingly in order not to overemphasize the desired outcome (Figure 21).

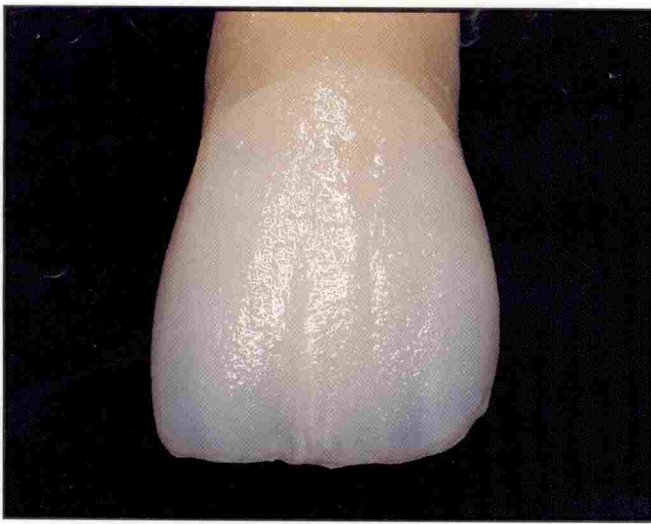

Figure 25. Artificial enamel — microfill applied onto the facial aspect.

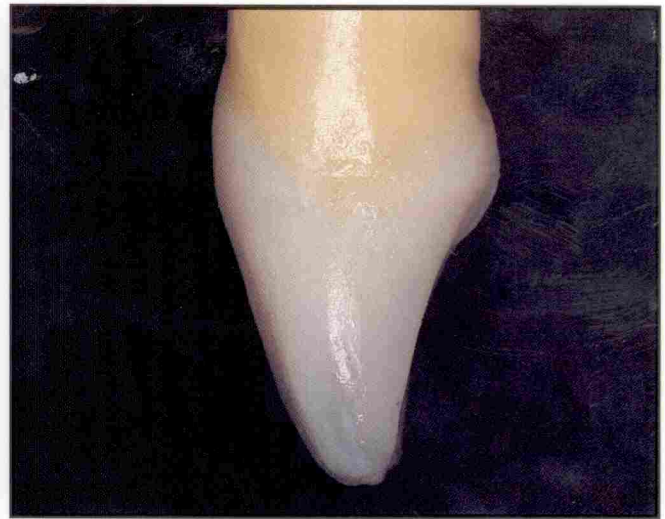

Figure 26. Artificial enamel — microfill applied onto the proximal aspect.

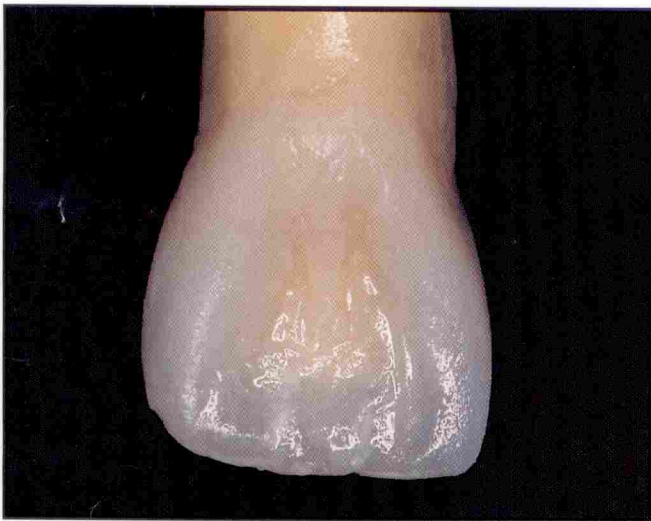

Figure 27. Artificial enamel — microfill applied onto the palatal aspect.

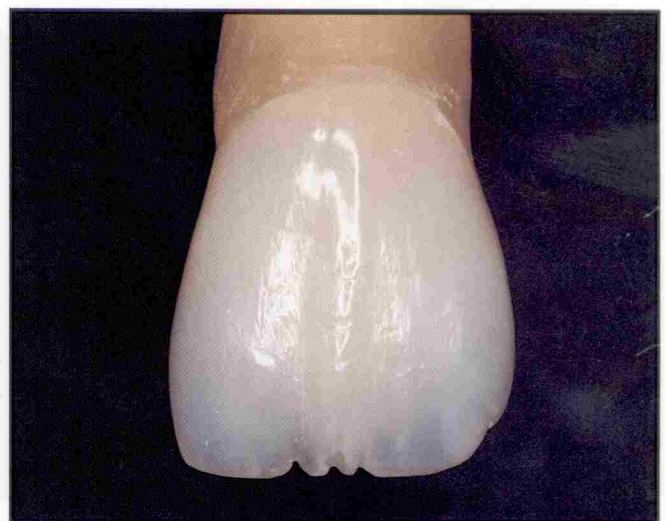

Figure 28. Final polished restoration — buccal aspect.

Opaquers, most frequently used to mask undesired dark spots in teeth or even restorations, can be of significant value when used to chromaturize mamelons, simulate craze lines, hypoplastic lesions, or any other type of stains (Figures 22 through 24). Several excellent materials are available for this purpose (eg, Kolor Plus, Kerr, Glendora, CA; Creative Color, Cosmedent, Chicago, IL).

Finally, care must be taken not to overbuild the artificial dentin which would then leave insufficient space for the final microfilled layer. This microfilled layer must completely cover the cervical, middle, and incisal thirds, imparting the final anatomic form to the restoration (Figures 25 through 27). Usually, the

shade of microfill that is used for the middle third can be used for the incisal third, depending on the particular case. If extra translucency is de-

**Perception of variations
in hues, chromas, and
values is necessary for
the incisal third.**

sired, and the intricate coloring must project through, a microfilled incisal should be layered over the entire underlying hybrid core, which consists

of the artificial mamelons and the translucent hybrid incisal. Either one of the previously mentioned enamel-like microfills for the middle third can be used for standard incisal cases whenever an enhanced translucency is desired. After the restoration is finished and polished, the intricacy of anatomical details and color variation can best be perceived (Figures 28 through 30).

SUMMARY AND CONCLUSION

It is possible today to restore anterior teeth to a high level of functional integrity and aesthetic excellence (Figures 31 and 32). Today's dentists are highly trained in the science of adhesive dentistry and are able to

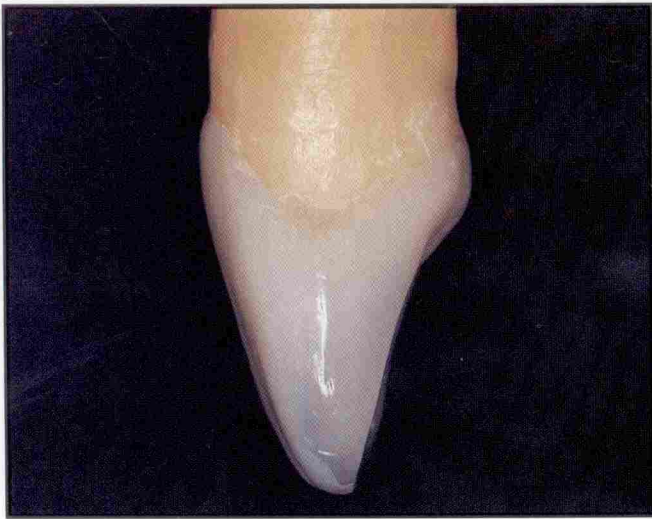

Figure 29. Final polished restoration — proximal aspect.

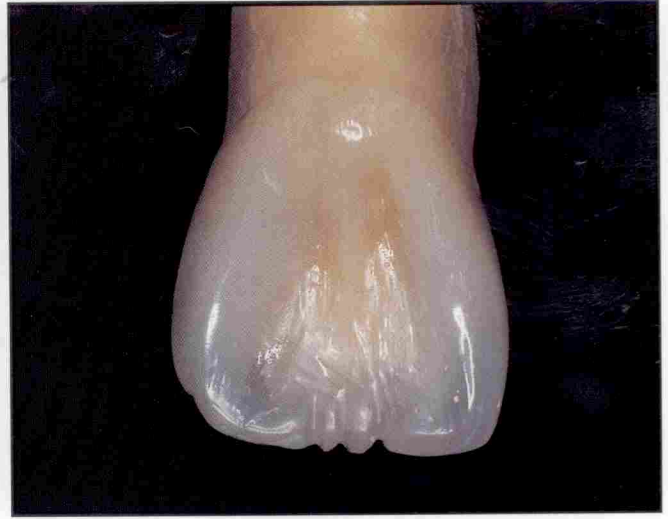

Figure 30. Final polished restoration — palatal aspect.

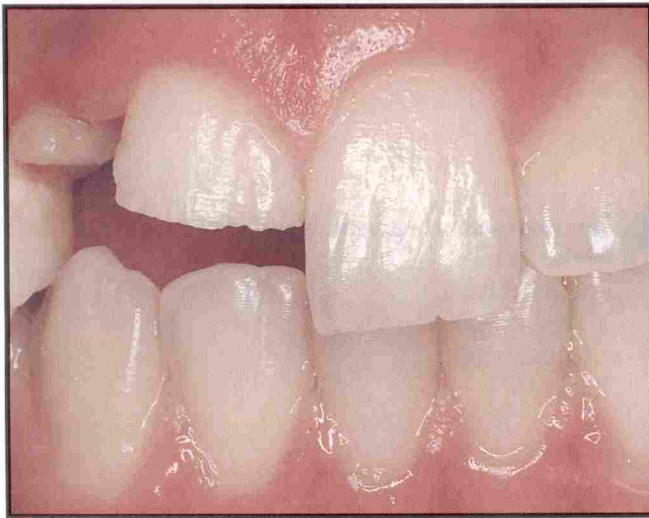

Figure 31. Preoperative facial view of fractured maxillary central and lateral incisors, due to a fall while skating.

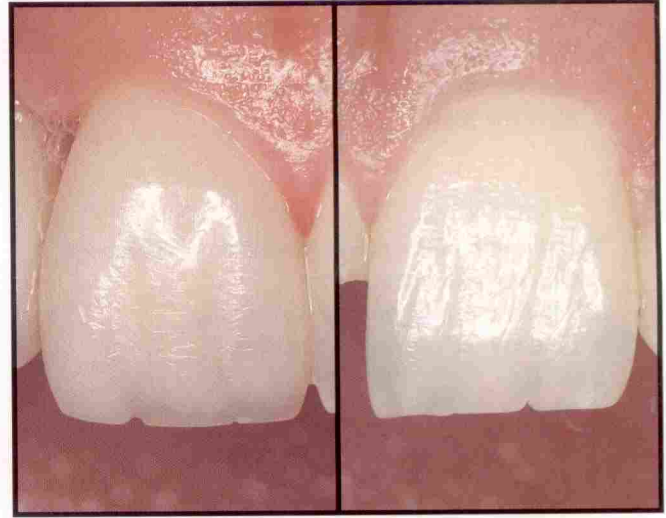

Figure 32. Postoperative close-up of both maxillary central incisors. Compare the life-like appearance of restored tooth #8 (left) when compared with the natural intact tooth #9 (right).

carry out the mechanical steps to achieve a sound restorative result quite easily. However, the artistic skills to achieve a highly aesthetic (ie, invisible) restoration at the same time, can sometimes prove elusive. This is because it requires a deep understanding of the components of color and their relationship to natural tooth structure and composite resin restorative materials. As in all art, it also requires a heightened sense of observation.

This article has attempted to show how we can use the structure of the natural tooth itself and the forces it is subjected to as a guide in achieving a restoratively sound and aesthetic result. If the clinician understands the relationship of hue,

chroma, and value to translucency and opacity and can relate these characteristics of natural teeth to the available composite resins and their modifiers, it will not be necessary to memorize formulas to aesthetically restore anterior teeth. It is not nearly as complex as it may seem. A future article will demonstrate how these principles are applied in actual clinical cases.

Acknowledgment

The primary author would like to express his most sincere thank you to the two co-authors, Drs. Denehy and Jackson, for their considerate assistance in the preparation of this article.

REFERENCES

1. Leinfelder K, Sluder T, Santos J, Wall J. Five-year clinical evaluation of anterior and posterior restorations of composite resin. *Oper Dent* 1980;5(2):57-65.
2. Leinfelder K. Posterior composite resins: The materials and their clinical performance. *JADA* 1995;126:663-676.
3. Vargas MA, Lunn PS, Fortin D. Translucency of human enamel in dentin. *J Dent Res* 1994;AADR Abstracts (Abstract #1747).
4. Morley J. The positive side of dentistry: An interview with Dr. Jeff Golub-Evans. *Dent Today* 1994;March:42.
5. Preston J, Bergen S. *Color Science and Dental Art. A Self-Teaching Program*. St. Louis: Mosby, 1980.
6. Muia P. *Esthetic Restorations: Improved Dentist Laboratory Communications*. Chicago: Quintessence, 1993.
7. Singer B. *Principles of Esthetics in Current Opinion in Cosmetic Dentistry*, 2nd Edition. Philadelphia: Current Science, 1994.
8. Vargas MA, Bouschlicher MR. Translucency/opacity of proprietary composite resins. *J Dent Res* 1995;AADR Abstracts (Abstract #1384).
9. Ubassy G. *Shape and Color — The Key to Successful Ceramic Restorations*. Hong Kong: Quintessence, 1993.
10. Buonocore M, Davila J. Restoration of fractured teeth with ultraviolet light polymerized bonding materials. *JADA* 1973;86:1349-1354.
11. Grippo J. Abfractons: A new classification of hard tissue lesions of teeth. *J Esthet Dent* 1991;3:9-14.
12. Miller M. The techniques: Class V resin in reality. *Reality* 1995;6:313.